

Volume 7  
Issue 2  
December 2023  
ISSN: 3027-5008 (Online)  
ISSN: 3027-5016 (Print)

# KOSOVA JOURNAL OF SURGERY

PAPERS PRESENTED AT THE THIRD CLINICAL  
CONGRESS OF THE KOSOVA COLLEGE OF  
SURGEONS, OCTOBER 12-15, 2023



- RIFAT LATIFI: PERSPECTIVE: Swimming Against the Tide and Making It to the Shore: The First Five Years of Kosova College of Surgeons
- BELLAL JOSEPH: The Reemerging Role of Whole Blood in Modern Trauma Care: Is the Whole Greater than the Sum of its Parts?
- RUSSELL J ANDREWS: Efficient Surgery/Neurosurgery: Cutting Costs and Cutting Time Without Cutting Corners
- KRISHNAN GANAPATHY: Quality of Death in Neurosurgical Practice: A 40-year Story from India

# Laparoscopic Nissen Fundoplication: Approach & Techniques

Sebastian K. Chung, Benjamin A. Palleiko, Demetrius Litwin

*Presented as State-of-the-art lecture at the 3<sup>rd</sup> Clinical Congress of Kosova College of Surgeons, Prishtina, Kosova, October 12-15, 2023*

**Corresponding author:**

**DEMETRIUS LITWIN, MD, MBA, FRCSC, FACS, FICS**

Department of Surgery, University of Massachusetts Chan Medical School,  
Worcester, Massachusetts, USA.

E-mail: [Demetrius.Litwin@umassmemorial.org](mailto:Demetrius.Litwin@umassmemorial.org)

## Abstract

The standard surgical treatment of gastroesophageal reflux disease (GERD) is fundoplication. Indications include failure of medical management, side effects of medications, complications including strictures, bleeding or asthma/aspiration pneumonia, and quality of life issues (ie. intractable symptoms or lifelong antireflux medication). The laparoscopic approach is safe and effective, but is associated with a relatively high rate of recurrent GERD and/or hernia. Surgeons must vigilantly adhere to the principles of appropriate workup, patient selection, and operate with technical precision in esophageal mobilization into the abdomen, crural closure, and creation of a floppy fundoplication. The presence of paraesophageal hernias and motility disorders may require variations in technique, such as substitution of Nissen (full 360-degree) fundoplication for a Toupet (partial 270-degree) fundoplication. This report is an overview of the general principles surgeons should adhere to when evaluating patients for surgical management of GERD. Specific technical steps will be described, with emphasis on the steps that require rigorous attention to detail for optimal outcomes. The anticipated postoperative course and common complications will be briefly reviewed.

**Key Words:** Laparoscopy, Nissen Fundoplication, Gastroesophageal Reflux Disease.

## Introduction

Gastroesophageal reflux disease (GERD) arises due to dysfunction of the lower esophageal sphincter (LES), resulting in reflux of acidic gastric contents into the esophagus and subsequent symptomatic esophagitis.<sup>1-6</sup> GERD is characterized by symptoms of heartburn, nausea and vomiting, and if untreated, can lead to complications including strictures, ulceration, bleeding or Barrett's esophagus (metaplasia associated with progression to esophageal adenocarcinoma).<sup>7</sup> Given the known association between GERD and obesity,<sup>8</sup> the incidence of GERD may likely rise in parallel with increasing BMI globally,<sup>9</sup> including in the Balkans.<sup>10</sup>

The Nissen Fundoplication,<sup>11</sup> first described by German physician Dr. Rudolf Nissen in 1956, is the current gold standard surgical operation for GERD, utilizing an encircling of the stomach around the esophagus to recreate LES function in order to reduce reflux of gastric contents superiorly into the esophagus. Indications for surgery include: failure of medical management, inability to take/pay for medications, complications such

as strictures, bleeding or asthma/aspiration pneumonia, and concerns with quality of life (i.e., symptoms of life-long antireflux medication). The first laparoscopic Nissen fundoplication was performed by Dallemagne in Belgium in 1991.<sup>12</sup> The laparoscopic approach proved to be safe and effective, resulting in equivalent short and long term outcomes and with a shorter length of stay when compared to open surgery, and has become the gold standard surgical treatment of GERD.<sup>8,13</sup>

### Preoperative Evaluation

While GERD is a clinical diagnosis largely based on a clinical history of typical reflux symptoms, supplementary testing is crucial in evaluating the appropriateness of the various medical and surgical therapy options.<sup>6</sup> Endoscopy is necessary to diagnose the presence of esophagitis or Barrett's esophagus and it will also demonstrate the presence of a hiatal hernia. If surgery is being contemplated, it is essential for every patient to have an upper endoscopy for evaluation within one year. Occasionally, a barium swallow is useful to outline the type of hiatus hernia, the size, and the possibility of an underlying "short esophagus." Prior to offering surgery, all patients undergo 24-hour pH monitoring and esophageal motility evaluation.

The 24-hour pH monitoring test is considered the gold standard for quantifying acid reflux.<sup>14,15</sup> Longer time periods can occasionally improve diagnostic sensitivity further. The pH study is generally conducted with a Bravo™ capsule implanted in the esophagus that can measure pH over a 24-hour period. Patients record heartburn events throughout this period which are correlated with pH in the esophagus at those time points. The DeMeester score is calculated from the total number of events (pH <4), longest episode of reflux, number of episodes over five minutes, and the extent of reflux in the supine and upright positions.<sup>14,15</sup> A DeMeester score of >14.7 (95th percentile) is traditionally considered a confirmation of GERD and to be predictive of a favorable response to operative intervention, though there is emerging data to suggest acid exposure time may be even more specific for GERD and predictive of improved outcomes.<sup>16</sup> High resolution manometry is another important aspect of the workup, and helps identify any evidence of esophageal dysmotility that might affect the approach to LES reconstruction.<sup>14</sup> A partial 270-degree Toupet fundoplication is performed in patients with significant esophageal dysmotility.

Finally, it is important to note that the workup of

GERD continues to evolve over time with continued technological advances. For example, impedance planimetry, or the EndoFLIP,<sup>17</sup> is a newly emerging technique that measures esophageal dynamics and can be performed in conjunction with upper endoscopy. We anticipate that, as data for these new technologies mature, the GERD landscape and indications for antireflux surgery may correspondingly evolve.

### Technical Steps

At our institution, five ports are used for the operation. Port placement is shown in Figure 1A and Figure 1B. Access to the abdomen is achieved via a Veress needle in the left upper quadrant, and a 12 mm port is placed. A high epigastric 5 mm port, supraumbilical 5 mm port, a right upper quadrant 5mm port, and a left paramedian 5 mm port are inserted and the patient placed in slight reverse Trendelenburg position. A Nathanson retractor is used in the right upper quadrant port to elevate the left lobe of the liver (Figure 1B). A laparoscopic 5 mm camera with a 30 degree scope is used through the supraumbilical port. In total, one 12 mm port (used for the introduction of sutures and laparoscopic sponges) and four 5 mm ports are required.

The operating room setup for this procedure is shown in Figure 2. The lead surgeon and assistant surgeon stand on the patient's left side with a video screen at head height, directly across from the surgeon and assistant. The lead surgeon operates through the high epigastric and left upper quadrant ports, while the assistant controls the camera in the supraumbilical port and assistant port in the left paramedian position.

After port placement, the left lobe of the liver is elevated with a Nathanson retractor (Figure 3A). The dissection is performed initially by opening the gastrohepatic omentum to the right crus with an energy device in an avascular region (Figure 3B-C), taking care to avoid a potential accessory or replaced left hepatic artery. The peritoneum overlying the right crus is dissected and the esophagus is distracted to avoid injury to the vagus nerve (Figure 3C-D). The phrenoesophageal membrane is divided and the esophagus is dissected off the left crus in a similar fashion. After freeing the esophagus from the right and left crura, a penrose drain is wrapped around the esophagus and used for traction to obtain at least 2-3 cm of intraabdominal esophagus without tension (Figure 5A-D and Figure 6A-D). The short gastric vessels are divided sequentially up to the level of the esophageal hiatus with



an energy device (Figure 7A-D). Occasionally, adipose retraction with a suture may be required for adequate exposure of the highest short gastric vessels (Figure 8A-D). The crura are approximated using 0 Ethibond sutures, leaving approximately 1 cm of space to accommodate the esophagus (Figure 10A-B).

The Nissen fundoplication is then performed, pulling the stomach 360 degrees posterior to the esophagus from patient left to right. A “floppy” fundoplication is ensured by lifting the apposed fundus wrap anteriorly such that approximately two esophageal diameters can fit within the wrap, making note to ensure symmetry (Figure 11A-D). While the use of a bougie has been described to assist with approximation, we omit the use of a bougie in this step given the risk of perforation.<sup>18-20</sup> This has been the senior author’s practice since 1992 following a bougie-related distal esophageal perforation and non-use of a bougie has been associated with a very low rate of dysphagia.<sup>20</sup> Prior to suturing the wrap in place, a single stitch held together with a metal clip can help to approximate the wrap and ensure proper positioning (Figure 12A-B). Three 0-silk sutures are used to suture the wrap, which typically measures 2.5 to 3 cm (Figure 12B-D and Figure 13A-B). The lowest part of the wrap should extend to the gastroesophageal junction without a gap of intervening normal esophagus between the wrap and the normal LES (Figure 13C-D).

While the Nissen fundoplication as described above is the primary antireflux surgery performed at our institution, adjuncts and modifications may be considered in select patients. For example, if a patient is found to have esophageal dysmotility on preoperative workup, a 270 degree Toupet fundoplication may be performed.<sup>21</sup> Furthermore, if a tension-free esophageal dissection cannot be safely achieved, a Collis gastroplasty may be considered, although it is rarely needed.<sup>22</sup>

### Postoperative Course, Complications and Outcomes

Patients are allowed to drink postoperatively on the day of surgery. On the first postoperative day, a liquid, pureed or soft diet is initiated, and the patient is discharged. Patients remain on an esophageal soft diet, avoiding bread, meats, and raw vegetables for at least two to four weeks, gradually introducing foods with greater consistency.

Intraoperative complications are infrequent. Pneumomediastinum can occur and occasionally lead to crepitus of the chest wall or neck, but it is rapidly resorbed and causes no symptoms.<sup>23</sup> Although splenic injury has been

described,<sup>24</sup> it is uncommon and to date has not been an issue for our group. Pneumothorax can occur, particularly when large hiatus hernias are dissected high in the mediastinum and the pleura is entered.<sup>23</sup> This does not typically pose a problem because ventilatory pressures are much higher than pneumoperitoneum, and ventilatory pressures can be increased in response. If a pneumothorax has occurred, we hyperinflate the lungs for ten to twelve seconds while pneumoperitoneum is released at the end of the case. This will successfully treat the pneumothorax but that must be confirmed with a postoperative chest X-ray. Rarely, the opening in the pleura is not large enough and it acts as a flap valve, so that carbon dioxide enters the pleural space but cannot escape. In those cases, when pneumothorax is appreciated, the pleural opening should be significantly enlarged so that the carbon dioxide gas in the pleural space can easily be pushed out of the pleural space with inflation of the lungs.

Although splenectomy has been reported in about 2% of cases in one series,<sup>24</sup> that has not been an issue in our hands, and one must be very meticulous in the dissection of the short gastric vessels to avoid significant bleeding.<sup>24</sup> The reported risk of esophageal injury has been as high as 1%, and can be further reduced by avoiding use of a bougie.<sup>18-20</sup> The risk of these injuries diminishes with increasing experience,<sup>25</sup> and aside from one bougie placement perforation early in the senior author’s experience, esophageal perforation has not occurred.<sup>20</sup>

All patients undergoing Nissen fundoplication develop some degree of dysphagia postoperatively, but this typically dissipates within four to six weeks.<sup>26-30</sup> Long-term dysphagia can occur and represents either a tight fundoplication, crural closure that is too tight, or more significant dysphagia than was recognized preop which was then subsequently worsened by the creation of a fundoplication.

Reported failure rates range from 3% to 30%, and are based on various definitions including recurrent GERD requiring the continued use of PPIs after surgery, or the need for reoperation.<sup>1-5</sup> Undoubtedly, some patients will recur because of a recurrent hiatus hernia, loosening of the wrap, or both.<sup>1,2,31-33</sup> Over time, many patients will be placed on PPIs at some point post-fundoplication, though it is unclear if the indications for post-fundoplication PPIs are for recurrent GERD (14% to 40%) or for other, softer indications.<sup>2,34,35</sup> Many patients placed on PPIs for GI tract symptomatology do not necessarily have recurrent reflux disease.<sup>2,34,35</sup>



Some degree of gas bloat symptomatology can occur postoperatively and can last for many months, but generally tends to improve over time.<sup>1,30,36</sup> Some degree of vagal denervation can occur intraoperatively while dissecting the esophagus. This is unusual in a standard Nissen, but in re-operative surgery, or surgery for gastric volvulus, this can occasionally occur leading to delay in gastric emptying causing prolonged bloating, fullness, and occasionally intractable nausea.<sup>31</sup>

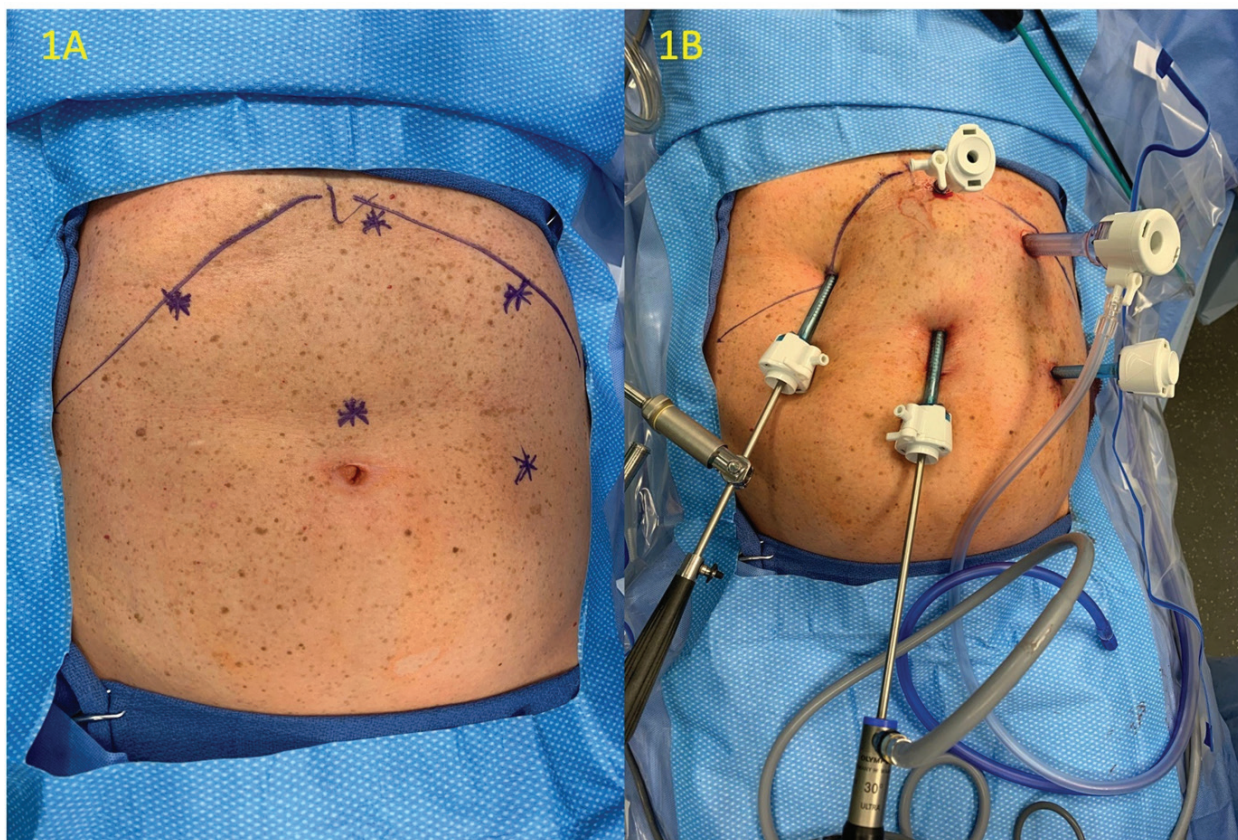
The most common reoperation is for recurrent GERD symptoms.<sup>2,29,31,35,37</sup> Occasionally, a “slipped fundoplication” where the stomach herniates up through the wrap, will present with either recurrent reflux, dysphagia, or both.<sup>1,30,36</sup> A recurrent hiatus hernia can occur with the previously created fundoplication in the chest, resulting

in an “intrathoracic fundoplication,” many of which will be asymptomatic. Finally, a paraesophageal hernia can occur, which requires require treatment when symptomatic.<sup>1,2,31-33</sup>

### Conclusion

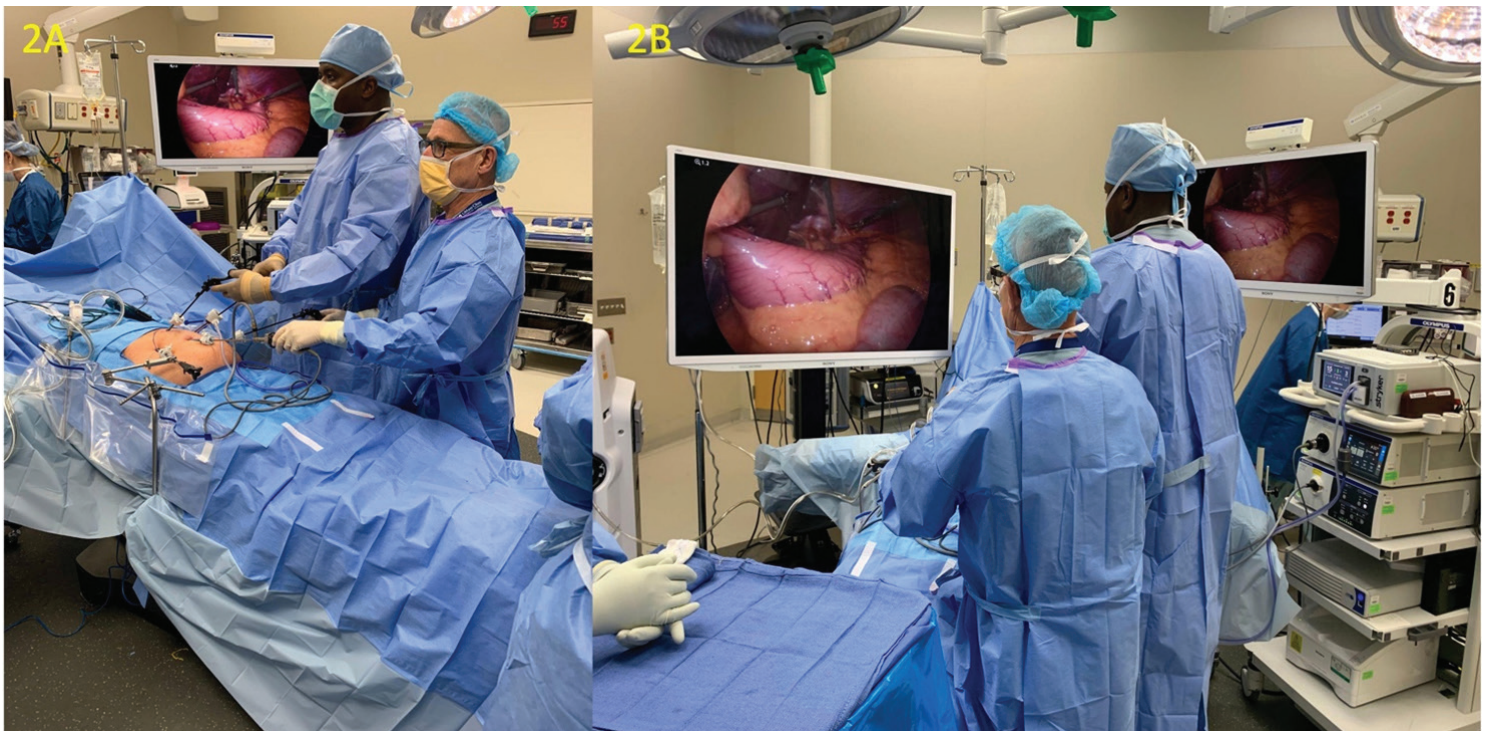Nissen fundoplication is an excellent operation to treat reflux disease. However, gradual separation of the crura and loosening of the wrap can occur leading to recurrence of both the hiatus hernia and reflux disease.<sup>31</sup> Certainly, the intraabdominal forces that led to the hiatus hernia in the first place are still there, and there are physiologic limitations to the strength and performance of the repairs. For this reason, meticulous attention to detail must be exercised when performing these operations.

### Figures:

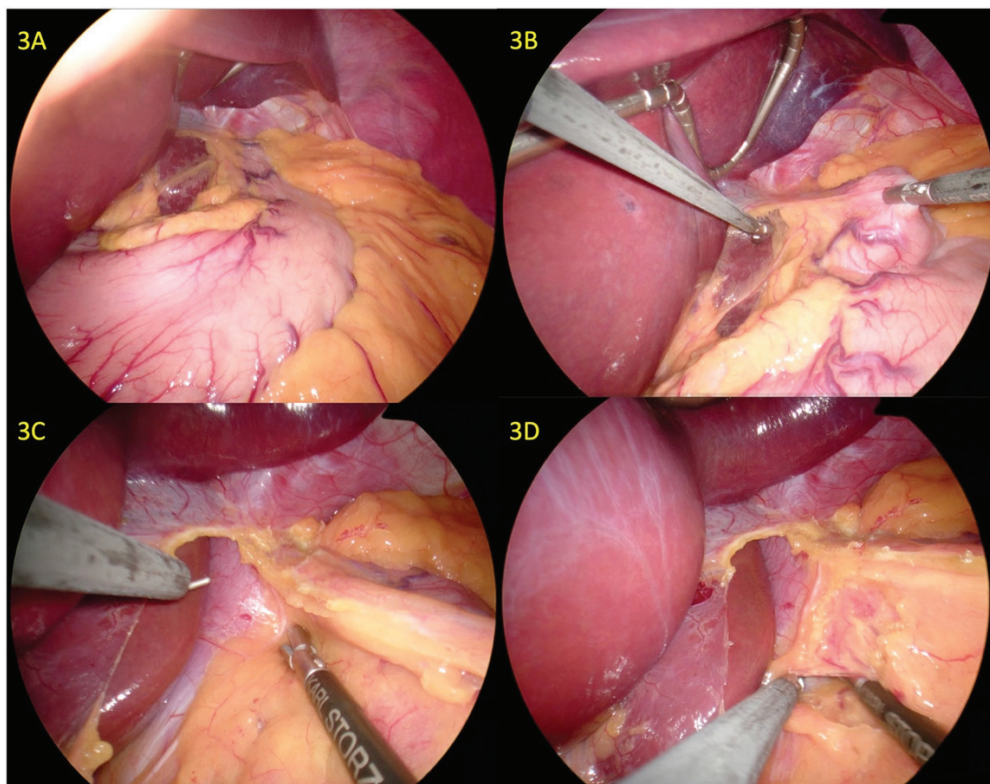


**Figure 1:** (A) Preoperative planning of port placements.  
(B) Ports placed with Nathanson retractor and laparoscopic camera inserted



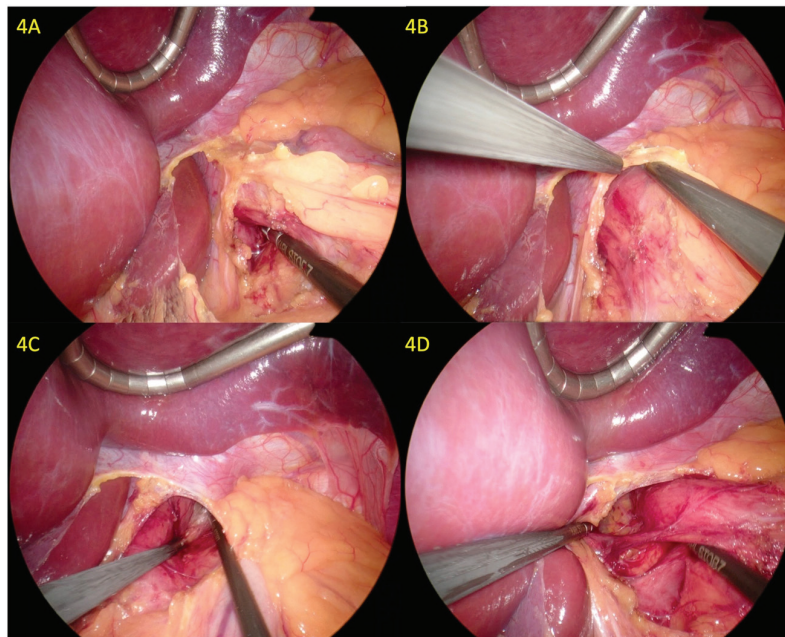


**Figure 2:** Operating room setup with surgeon and assistant positioning

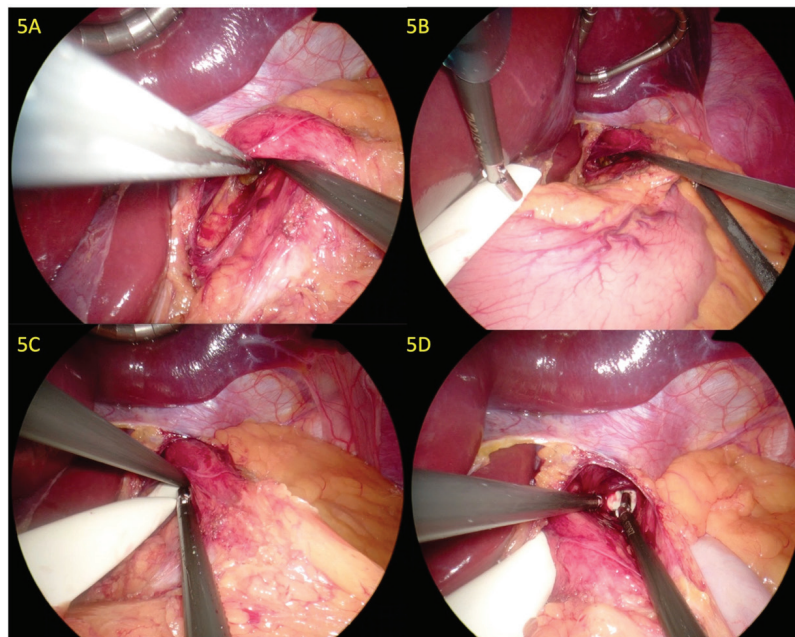


**Figure 3:** (A) Typical view of the esophageal hiatus with the left lobe of liver elevated with a Nathanson retractor. (B) The dissection begins by creating a window in the gastrohepatic omentum and (C) extending that to the right crus. There is a line of separation in the peritoneum between the right crus and the paraesophageal fat which is entered along the right crus and then an avascular plane (D) is located separating the paraesophageal fat and the crus which is then extended to mobilize the esophagus.



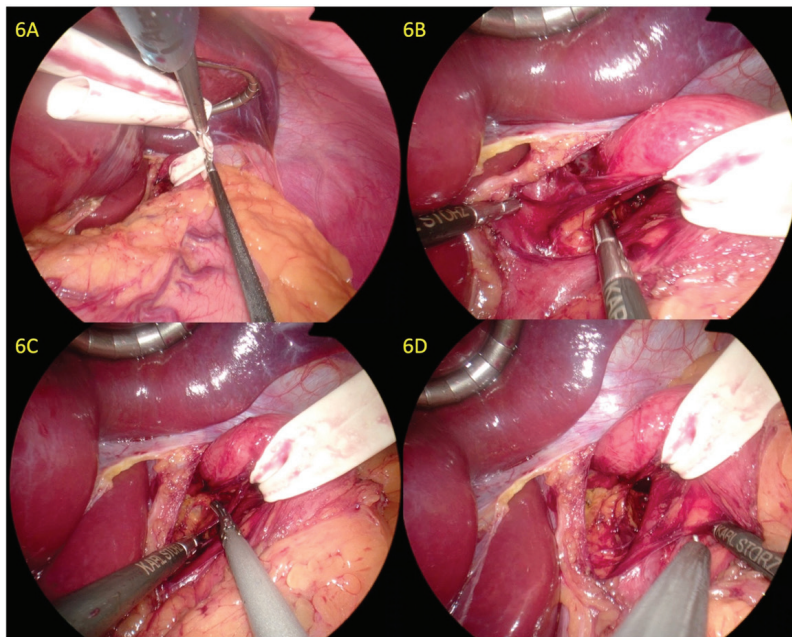


**Figure 4:** (A) Sequential mobilization along the crus distracting the esophagus from the crus is carried out. (B) The phrenoesophageal membrane is divided. (C) A similar blunt dissection is carried along the left crus to distract the esophagus from the left crus in the avascular plane. (D) The esophagus is progressively mobilized and elevated to distract the esophagus and allow for the division of further attachments which one can see here.

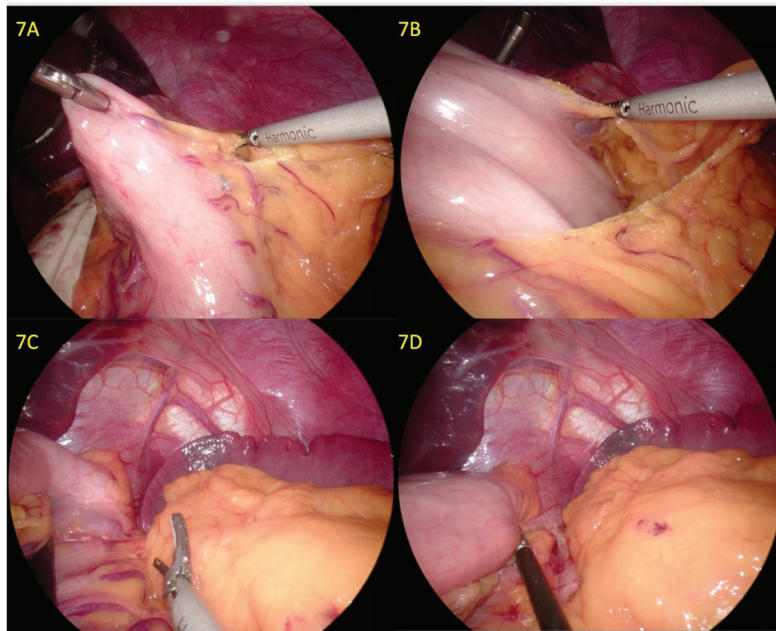


**Figure 5:** (A) Progressive mobilization and creation of a retroesophageal window. (B,C) A Penrose drain is situated so that it can be placed in the retroesophageal window. (D) The Penrose drain is found on the other side in the retroesophageal window alongside the left crus

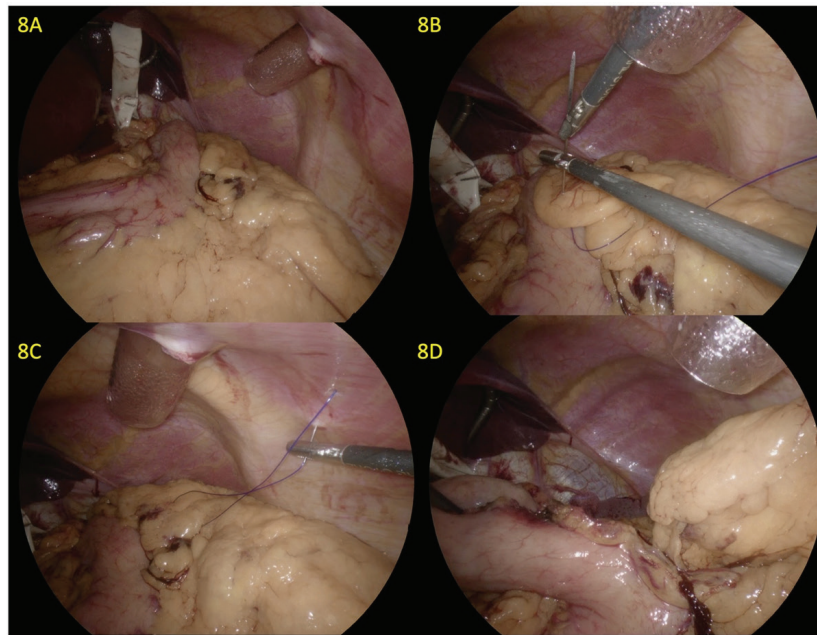




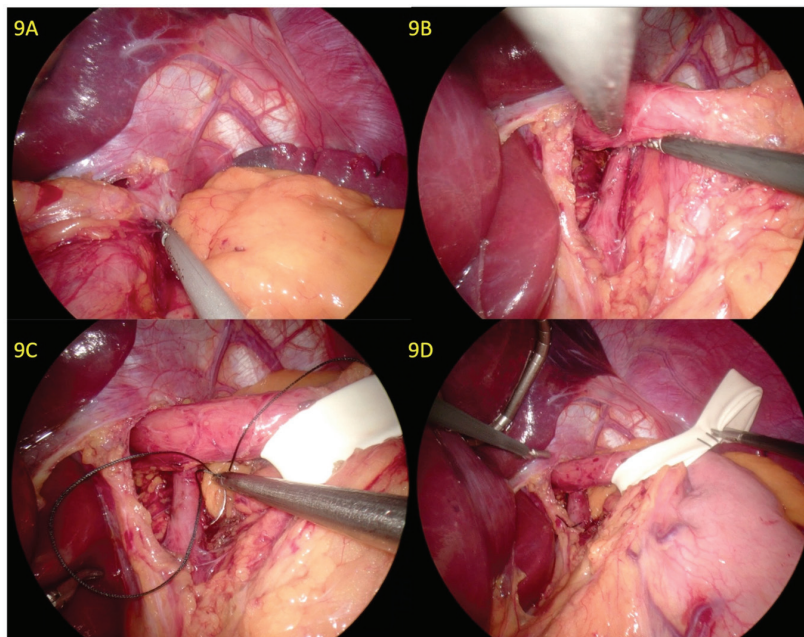
**Figure 6:** (A) The Penrose drain is clipped together and then utilized to retract the esophagus. (B, C) Distraction of the esophagus allows for division of further attachments higher up in the mediastinum so that an adequate length of esophagus can be mobilized into the abdomen without tension. (D) Remaining attachments over the left crus are then divided to fully expose the left crus



**Figure 7:** (A) Once the hiatus is adequately dissected, attention is directed towards the short gastric vessels. This begins with creation of a window in the greater omentum. (B, C) The omentum is then sequentially divided all the way up by taking the short gastric vessels to the level of the left crus. This requires progressive distraction of the stomach to the patient's right and I find that grasping the posterior aspect of the stomach helps with distraction as one gets closer to the hiatus. Either the Harmonic scalpel™ or an advanced bipolar tool is utilized for hemostasis. In the early days of our experience we used to sequentially isolate, clip and divide the vessels but that is much more slow and tedious. (D) In order to gain adequate mobilization for fundoplication, the highest short gastrics must be divided.

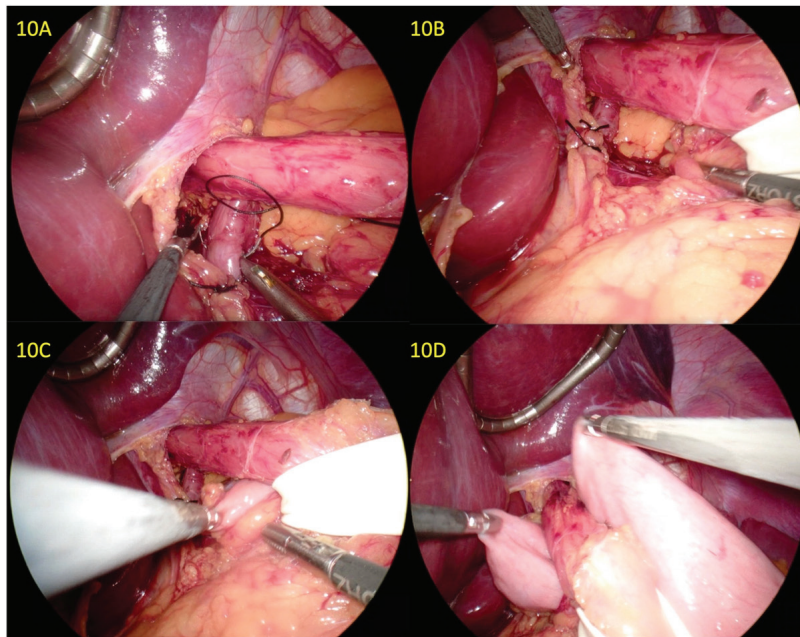


**Figure 8:** (A) In the case of a patient with a significant amount of intra-abdominal adipose tissue, a Keith needle can be passed into the abdomen and the adipose tissue of the omentum is speared with a suture at multiple levels in order to broadly retract the omental fatty tissue with a suture (B). The Keith needle is then passed out of the abdomen (C), retracting the adipose tissue and allowing for adequate exposure of the highest short gastric arteries by evacuating the omentum from the left upper quadrant (D).

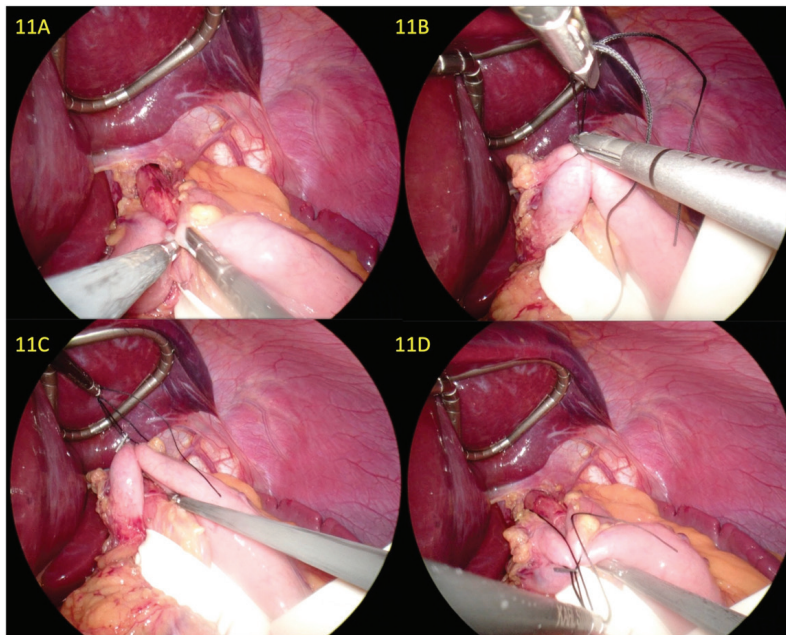


**Figure 9:** (A) The left crus is then exposed from the patient's left-hand side. (B) The crura are now completely exposed. (C) One can then begin to close the hiatus. Bites of sufficient size are needed of the crura to bring them together and a non-absorbable 0 suture is used, in this case silk. (D) The first suture is tied.



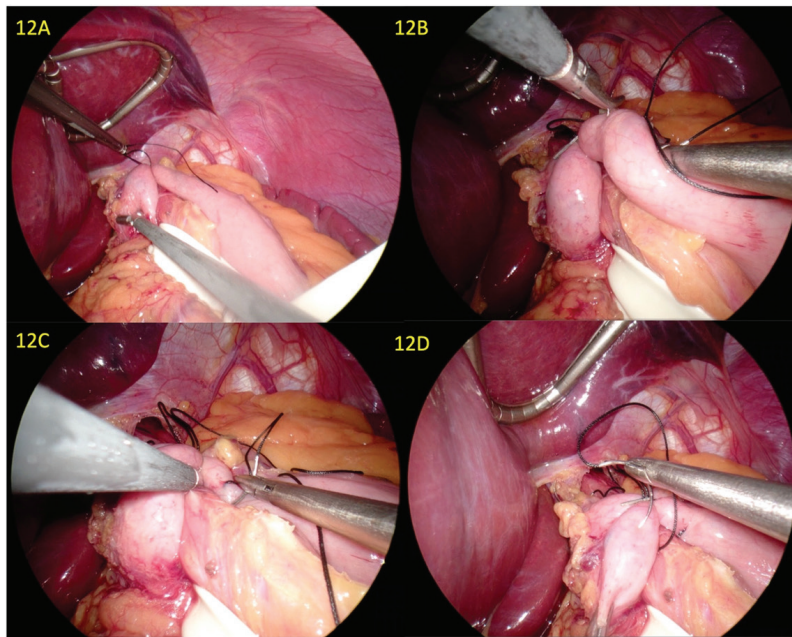


**Figure 10:** (A, B) A second suture is placed and tied. We aim to narrow the hiatus to 1-2 fingerbreadths which was the goal in open surgery historically. In essence, the hiatus must be loose enough to allow a bolus of food to come through the esophagus. There should be 2-3 cm of space around the esophagus which correlates to 1-2 fingerbreadths. (C, D) With the esophagus distracted to the patient's left, the surgeon is able to grasp the fundus of the stomach and gradually pull it around the posterior aspect of the esophagus. An adequate amount of stomach must be pulled through.

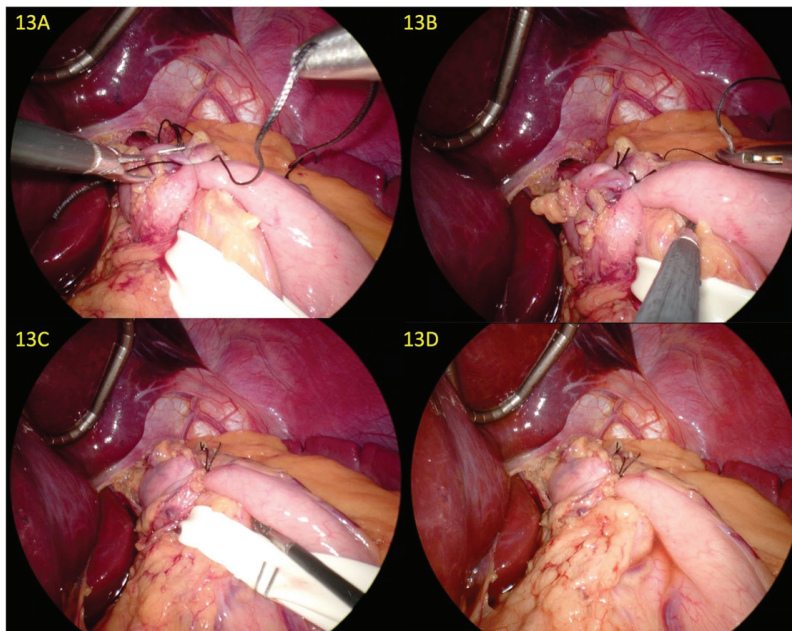


**Figure 11:** (A) Once the stomach is pulled through it is imperative that the fundoplication is floppy enough so that long-term dysphagia is not a consequence of the operation. I utilize a simple trick that I routinely use and teach. Once the suitability of the amount of stomach is demonstrated (A), I place a stitch which I then hold together with a clip (B). This allows me to pull up on the stomach which demonstrates that there is sufficient room beneath the wrap for distention of the esophagus. I imagine that an additional esophageal diameter can be placed underneath the wrap as depicted in 10C (C), and with further manipulation by pulling down, one can see that the wrap will also be very symmetrical (D).





**Figure 12:** (A) The wrap is now positioned and you can see that this is the desired placement of the fundoplication. (B) With the esophagus being held together by the first stitch, the two edges are very close together and suturing is very easy with no tension on the repair. In essence, the clipped suture holds things together to make completion of a fundoplication a much easier suturing maneuver. (C, D) One can see that an adequate bite of the stomach must be taken, an adequate bite of esophagus, and a sufficient bite of the opposite side in order to create a robust fundoplication.



**Figure 13:** (A) The suture that was just placed is easy to tie because there is no tension. (B) The suture that was held by the clip is now tied, and the third and final stitch is being placed. Typically I place three sutures in order to create a 2.5 to 3.0 cm fundoplication that ends just at the level of the patient's lower esophageal sphincter. (C, D) The completed fundoplication

## References

1. Fuchs KH, Breithaupt W, Varga G, Babic B, Eckhoff J, Meining A. How effective is laparoscopic redo-antireflux surgery? *Dis Esophagus Off J Int Soc Dis Esophagus*. 2022;35(3):doab091. doi:10.1093/dote/doab091
2. Markar SR, Arhi C, Wiggins T, et al. Reintervention After Antireflux Surgery for Gastroesophageal Reflux Disease in England. *Ann Surg*. 2020;271(4):709-715. doi:10.1097/SLA.0000000000003131
3. Obeid NR, Altieri MS, Yang J, et al. Patterns of reoperation after failed fundoplication: an analysis of 9462 patients. *Surg Endosc*. 2018;32(1):345-350. doi:10.1007/s00464-017-5682-y
4. Zhou T, Harnsberger C, Broderick R, et al. Reoperation rates after laparoscopic fundoplication. *Surg Endosc*. 2015;29(3):510-514. doi:10.1007/s00464-014-3660-1
5. Lamb PJ, Myers JC, Jamieson GG, Thompson SK, Devitt PG, Watson DI. Long-term outcomes of revisional surgery following laparoscopic fundoplication. *Br J Surg*. 2009;96(4):391-397. doi:10.1002/bjs.6486
6. Gyawali CP, Kahrilas PJ, Savarino E, et al. Modern diagnosis of GERD: the Lyon Consensus. *Gut*. 2018;67(7):1351-1362. doi:10.1136/gutjnl-2017-314722
7. Wu AH, Tseng CC, Bernstein L. Hiatal hernia, reflux symptoms, body size, and risk of esophageal and gastric adenocarcinoma. *Cancer*. 2003;98(5):940-948. doi:10.1002/cncr.11568
8. Eshraghi N, Farahmand M, Soot SJ, Rand-Luby L, Deveney CW, Sheppard BC. Comparison of outcomes of open versus laparoscopic Nissen fundoplication performed in a single practice. *Am J Surg*. 1998;175(5):371-374. doi:10.1016/S0002-9610(98)00049-X
9. Blüher M. Obesity: global epidemiology and pathogenesis. *Nat Rev Endocrinol*. 2019;15(5):288-298. doi:10.1038/s41574-019-0176-8
10. Tarp J, Jarani J, Muca F, Spahi A, Grøntved A. Prevalence of overweight and obesity and anthropometric reference centiles for Albanian children and adolescents living in four Balkan nation-states. *J Pediatr Endocrinol Metab JPEM*. 2018;31(11):1199-1206. doi:10.1515/jpem-2018-0253
11. Nissen R. [A simple operation for control of reflux esophagitis]. *Schweiz Med Wochenschr*. 1956;86(Suppl 20):590-592.
12. Dallemagne B, Weerts JM, Jehaes C, Markiewicz S, Lombard R. Laparoscopic Nissen fundoplication: preliminary report. *Surg Laparosc Endosc*. 1991;1(3):138-143.
13. Salminen P, Hurme S, Ovaska J. Fifteen-year outcome of laparoscopic and open Nissen fundoplication: a randomized clinical trial. *Ann Thorac Surg*. 2012;93(1):228-233. doi:10.1016/j.athoracsur.2011.08.066
14. DeMeester TR, Johnson LF. Evaluation of the Nissen antireflux procedure by esophageal manometry and twenty-four hour pH monitoring. *Am J Surg*. 1975;129(1):94-100. doi:10.1016/0002-9610(75)90174-9
15. Worrell SG, Greene CL, DeMeester TR. The state of surgical treatment of gastroesophageal reflux disease after five decades. *J Am Coll Surg*. 2014;219(4):819-830. doi:10.1016/j.jamcollsurg.2014.05.018
16. Amundson JR, Zukancic H, Kuchta K, et al. Acid exposure time better predicts outcomes following anti-reflux surgery than DeMeester score. *Surg Endosc*. 2023;37(8):6577-6587. doi:10.1007/s00464-023-10164-0
17. Donnan EN, Pandolfino JE. EndoFLIP in the Esophagus: Assessing Sphincter Function, Wall Stiffness, and Motility to Guide Treatment. *Gastroenterol Clin North Am*. 2020;49(3):427-435. doi:10.1016/j.gtc.2020.04.002
18. Schauer PR, Meyers WC, Eubanks S, Norem RF, Franklin M, Pappas TN. Mechanisms of gastric and esophageal perforations during laparoscopic Nissen fundoplication. *Ann Surg*. 1996;223(1):43-52. doi:10.1097/00000658-199601000-00007
19. Patterson EJ, Herron DM, Hansen PD, Ramzi N, Standage BA, Swanström LL. Effect of an esophageal bougie on the incidence of dysphagia following nissen fundoplication: a prospective, blinded, randomized clinical trial. *Arch Surg Chic Ill 1960*. 2000;135(9):1055-1061; discussion 1061-1062. doi:10.1001/archsurg.135.9.1055
20. Novitsky YW, Kercher KW, Callery MP, Czerniach DR, Kelly JJ, Litwin DEM. Is the use of a bougie necessary for laparoscopic Nissen fundoplication? *Arch Surg Chic Ill 1960*. 2002;137(4):402-406. doi:10.1001/archsurg.137.4.402
21. St Peter SD, Swain JM. Achalasia: a comprehensive review. *Surg Laparosc Endosc Percutan Tech*. 2003;13(4):227-240. doi:10.1097/00129689-200308000-00002
22. Orringer MB, Sloan H. An improved technique for the combined Collis-Belsey approach to dilatable esophageal strictures. *J Thorac Cardiovasc Surg*. 1974;68(2):298-302.
23. Pohl D, Eubanks TR, Omelanczuk PE, Pellegrini CA. Management and outcome of complications after laparoscopic antireflux operations. *Arch Surg Chic Ill 1960*. 2001;136(4):399-404. doi:10.1001/archsurg.136.4.399
24. Flum DR, Koepsell T, Heagerty P, Pellegrini CA. The nationwide frequency of major adverse outcomes in antireflux surgery and the role of surgeon experience, 1992-1997. *J Am Coll Surg*. 2002;195(5):611-618. doi:10.1016/s1072-7515(02)01490-4
25. Gill J, Booth MI, Stratford J, Dehn TCB. The extended learning curve for laparoscopic fundoplication: a cohort analysis of 400 consecutive cases. *J Gastrointest Surg Off J Soc Surg Aliment Tract*. 2007;11(4):487-492. doi:10.1007/s11605-007-0132-0
26. Dallemagne B, Weerts J, Markiewicz S, et al. Clinical results of laparoscopic fundoplication at ten years after surgery. *Surg Endosc*. 2006;20(1):159-165. doi:10.1007/s00464-005-0174-x

27. Strate U, Emmermann A, Fibbe C, Layer P, Zornig C. Laparoscopic fundoplication: Nissen versus Toupet two-year outcome of a prospective randomized study of 200 patients regarding preoperative esophageal motility. *Surg Endosc.* 2008;22(1):21-30. doi:10.1007/s00464-007-9546-8
28. Walle KV, Funk LM, Xu Y, et al. Persistent Dysphagia Rate After Antireflux Surgery is Similar for Nissen Fundoplication and Partial Fundoplication. *J Surg Res.* 2019;235:52-57. doi:10.1016/j.jss.2018.09.036
29. Dominitz JA, Dire CA, Billingsley KG, Todd-Stenberg JA. Complications and antireflux medication use after antireflux surgery. *Clin Gastroenterol Hepatol Off Clin Pract J Am Gastroenterol Assoc.* 2006;4(3):299-305. doi:10.1016/j.cgh.2005.12.019
30. Rantanen TK, Oksala NKJ, Oksala AK, Salo JA, Sihvo EIT. Complications in antireflux surgery: national-based analysis of laparoscopic and open fundoplications. *Arch Surg Chic Ill 1960.* 2008;143(4):359-365; discussion 365. doi:10.1001/archsurg.143.4.359
31. Ljungdahl JS, Rubin KH, Durup J, Houliand KC. Reoperation after antireflux surgery: a population-based cohort study. *Br J Surg.* 2020;107(12):1633-1639. doi:10.1002/bjs.11672
32. Horgan S, Pohl D, Bogetti D, Eubanks T, Pellegrini C. Failed antireflux surgery: what have we learned from reoperations? *Arch Surg Chic Ill 1960.* 1999;134(8):809-815; discussion 815-817. doi:10.1001/archsurg.134.8.809
33. Furnée EJB, Draaisma WA, Broeders IAMJ, Gooszen HG. Surgical reintervention after failed antireflux surgery: a systematic review of the literature. *J Gastrointest Surg Off J Soc Surg Aliment Tract.* 2009;13(8):1539-1549. doi:10.1007/s11605-009-0873-z
34. Maret-Ouda J, Wahlin K, El-Serag HB, Lagergren J. Association Between Laparoscopic Antireflux Surgery and Recurrence of Gastroesophageal Reflux. *JAMA.* 2017;318(10):939-946. doi:10.1001/jama.2017.10981
35. Wijnhoven BPL, Lally CJ, Kelly JJ, Myers JC, Watson DI. Use of antireflux medication after antireflux surgery. *J Gastrointest Surg Off J Soc Surg Aliment Tract.* 2008;12(3):510-517. doi:10.1007/s11605-007-0443-1
36. Hahnloser D, Schumacher M, Cavin R, Cosendey B, Petropoulos P. Risk factors for complications of laparoscopic Nissen fundoplication. *Surg Endosc.* 2002;16(1):43-47. doi:10.1007/s004640090119
37. McKinley SK, Dirks RC, Walsh D, et al. Surgical treatment of GERD: systematic review and meta-analysis. *Surg Endosc.* 2021;35(8):4095-4123. doi:10.1007/s00464-021-08358-5